

HISTOLOGICAL EXAMINATION OF RETINAL FUNCTION AND THE EFFECTS OF CURCUMA LONGA ON MEMORY CORRECTION IN EXPERIMENTAL OLFACTORY BULBECTOMY RAT MODELS

Ulduz Gashimova¹, Rubaba Guliyeva^{2*}, Kamala Javadova¹,
Arzu Ibishova², Elmira Panakhova¹

¹Institute of Physiology, Ministry of Science and Education, Baku, Azerbaijan

²Azerbaijan Medical University, Baku, Azerbaijan

Abstract. According to the latest literature data, histological studies of the retina in animal models of experimental Alzheimer's disease prove invaluable for identifying the disease in its early stages. The effects of plant antioxidants in disease rehabilitation can be determined by histological analysis of the retina. For this purpose, rats were used as the research object. Experimental animals were trained in the Morris maze to form and study spatial memory. To study the effects of herbal substances on memory correction curcuma was used in experimental animals. Histological analysis of the retina was comparatively analyzed in control, bulbectomized animals and curcuma-treated animals after bulbectomy. The histological materials obtained show that curcuma has a neuroprotective effect on histological changes animal retinas after bulbectomy and dysfunctions accompanied by deterioration of visual memory.

Keywords: *Memory, curcuma, rat, retina, bulbectomy.*

***Corresponding Author:** Rubaba Guliyeva, Azerbaijan Medical University, Baku, Azerbaijan,
e-mail: kulrub@mail.ru

Received: 23 November 2023;

Accepted: 6 February 2024;

Published: 16 April 2024.

1. Introduction

Literary materials related to clinical and experimental studies of Alzheimer's disease (AD) indicate its increase in frequency and rejuvenation (Wang *et al.*, 2017; Yoon *et al.*, 2019). Several clinical and histological studies indicate that the neurodegenerative process affecting the brain also affects the retina of AD patients. The retina is physically connected to the brain through optic nerves axon, in addition, the brain and retina are morphologically and physiologically very similar (Patton *et al.*, 2005). The close connections between the brain and the retina are used in various experimental models to study neurodegenerative processes (Moons *et al.*, 2022; Suh *et al.*, 2023). In modern literature, information is increasingly found about the presence of a number of visual dysfunctions in patients with AD. Thus, patients experience symptoms such as disturbances in color vision and contrast sensitivity, thinning of the retinal layers and changes in electrophysiological parameters (Asanad *et al.*, 2019; Ashok *et al.*, 2020). The

How to cite (APA):

Gashimova, U., Guliyeva, R., Javadova, K., Ibishova, A. & Panakhova, E. (2024). Histological examination of retinal function and the effects of curcuma longa on memory correction in experimental olfactory bulbectomy rat models. *Advances in Biology & Earth Sciences*, 9(1), 216-222 <https://doi.org/10.62476/abes9216>

study of such signs in the early stages of the disease can become a very important approach in the diagnosis and monitoring of the pathological process (Panahkova *et al.*, 2022; Zhang *et al.*, 2021; Zuhair *et al.*, 2023). However, the diagnostic value of detected markers of the neurodegenerative process in patients with AD during an ophthalmological examination still remains controversial. Since data from morphological studies reveal markers of neurodegeneration in various parts of the visual pathway, the nature of visual impairment in AD is still debated (Alber *et al.*, 2024; Heide *et al.*, 2024). Currently, the main goal of available treatment methods for the rehabilitation of the disease is to reduce the neurotoxic effect of amyloid proteins. Due to its neuroprotective effect, it is considered more convenient to use herbal medicines (*Panax jenseñen*, *Ginkgo biloba*, *Bacopa monnieri*, *Withania somnifera*, *Curcuma longa*, *Lavandula angustifolia*) from the point of view of the absence of negative consequences (Fernandes *et al.*, 2022; Long *et al.*, 2022; Pradeep *et al.*, 2022; Tao *et al.*, 2023). One such plant is widely used in the treatment of neurodegenerative diseases and is known in the scientific literature as Curcumin Longa. Curcumin inhibits the formation of beta-amyloid plaques and promotes their destruction and also attenuates tau hyperphosphorylation (Wu *et al.*, 2022). Thus, curcumin may be more effective than current treatments. In the scientific literature, curcumin is presented as a promising treatment for age-related brain diseases, including the main problems of using curcumin in the treatment of AD and ways to overcome them and specific recommendations for optimal dosing are also given (Furlan *et al.*, 2018; Teter *et al.*, 2019). Thus, in an era of rapid increase in blood pressure, it seems relevant to study the function and structural changes of the retina, as well as the effect of plant extracts on the course of the disease with the aim of rehabilitation in the early stages of the disease.

2. Objects and research methodology

Animal care and experimental studies were carried out in accordance with the rules of the Guide for the Care and Use of Laboratory Animals (NIH Guide for the Care and Use of Laboratory Animals) and their compliance (Guide on Care and Use, 2017).

Experimental model was created on white outbred rats weighing 250-300 g. The Morris water maze was used to study the spatial behavior and memory of animals. The animals were divided into 3 groups. Group I – intact, group II - those who underwent bulbectomy. The operations were performed under sterile conditions under general anesthesia. The drug calypsol was used as anesthesia. For 250-300 g of animal weight, 0.5 mg of calypsol was injected into the abdominal cavity. The amygdala was destroyed with a microneedle. Group III - to study the effect of plant-derived substances on neurodegenerative diseases experimental animals who underwent bulbectomy were given curcuma for 21, 90, 180 days. The solution was prepared as follows: 2.5 mg of curcuma powder was dissolved in 50 ml of boiled cooled water. Afterwards they tested a water maze and then histological sections of the eye were examined under a light microscope.

2. Results and discussion

In accordance with the goals and objectives of the study, the research was carried out in several stages. The animals were first trained in a Morris maze. The Morris water maze is known to be a key test for studying spatial learning and memory in experimental animals. The rats were released into a tank of water, from which there is no exit, but there is an invisible (the water is tinted, clouded) underwater platform, which can be a refuge:

after searching and finding it, the animal can get out of the water. Gradually, the time it took the rat to travel from the starting point to finding the platform shortens and the path becomes simpler. This indicates that the animal has formed an idea of the spatial location of the platform. This mental map may be more or less accurate and in order to determine the extent to which the rat remembered the position of the platform, the platform was moved to a new position. In this case, the time the rat spends above the previous location of the platform is an indicator of memory trace powers. During testing, the time it takes the animal to find the platform is measured. Training is considered successful if the response time to escape on the platform, the distance traveled from the place of placement in the water to the platform and the total distance between the center of the rat and the platform decreases.

Before bulbectomy, animals were trained to find a platform in Morris' water maze. The training lasted 2 days. Rats were put into a maze to find an invisible platform and the time was recorded. The animals found this platform in the interval from 15 to 38 s., which averaged 27.8 ± 10.24 s. After bulbectomy, after 2.5 months of rehabilitation, intact animals and olfactory bulbectomy rat models were tested in the Morris water maze.

If before bulbectomy the rats found the hidden platform on average within 27.8 ± 10.24 s., then after the operation the time to find the platform increased on average to 81.0 ± 10.86 s.

When analyzing the results of testing in Morris water maze, it is important that the measurement of time that a rat uses to complete the test can hardly be called an objective criterion for studying spatial learning and memory, since its value significantly depends on the swimming speed of the animal in the tank. In this regard, during testing we determined the time that the rat spent at the walls of the pool and in the target quadrant (in the area located in close proximity to the invisible platform).

The period of stay of rats with the AD model at the walls of the pool (38.61 ± 9.47 s.) exceeded the same indicator for intact rats (11.23 ± 3.51 s.) by 3.4 times ($p < 0.01$). The average time spent in the target segment for intact rats was 12.68 ± 4.30 s., for rats that underwent bulbectomy - 30.18 ± 8.56 s., which is statistically significantly longer (2.4 times, $p < 0.05$). 7 days after the injury, their eyes were examined microscopically.

The next step was to study the effect of curcuma on spatial behavior and memory. In order to study the curcuma actions dynamics at this stage, the animals were divided into 3 groups.

Group A - animals with tissue damage to the bulbar part of the brain. Each of the animals was regularly given 250 mg of curcuma extract suspension, tested in a water maze and on the 21st day, the eyes were examined microscopically.

Group B - animals with tissue damage to the bulbar part of the brain. Each of the animals was regularly given 250 mg of curcuma extract suspension, tested in a water maze and on the 90th day their eyes were examined microscopically.

Group C - animals with tissue damage to the bulbar part of the brain. Each of the animals was regularly given 250 mg of curcuma extract suspension, tested in a water maze and on the 180th day their eyes were examined microscopically.

After 2.5 months, the rats that had not undergone bulbectomy (intact) also found the invisible platform within 20-30 s., as before. Animals with bulbectomy found the invisible platform within 70-80 s. After administering curcuma to rats with experimental AD, the time spent on the platform was compared for rats of all groups. Group A found the invisible platform within 60-65 s., group B within 50-55 s., group C within 40-42 s. (Figure 1).

On the first day, rats of group II found the hidden platform in an average of 80.2 ± 9.74 s; on the second day, the search time decreased by 1.1 times and amounted to an average of 69.5 ± 9.11 s. Animals of group III with the AD model and received 2.5 mg of curcuma found the platform in 84.7 ± 8.92 s. on the first day and on the second day the search time decreased by 1.5 times ($p < 0.05$), averaging 56.3 ± 9.0 s.

Noteworthy was the fact that rats of group III, which received curcuma, stayed in the target segment of the Morris water maze longer than intact animals. Rats that received curcuma stayed in the target segment 1.7 times ($p < 0.05$) longer than controls. Thus, the positive effect of curcuma on memory was observed from the third day of training and reached its maximum on the seventh day of testing.

In order to study the neuroprotective effect of curcuma on the retina, animals were subjected to histological examination after each stage.

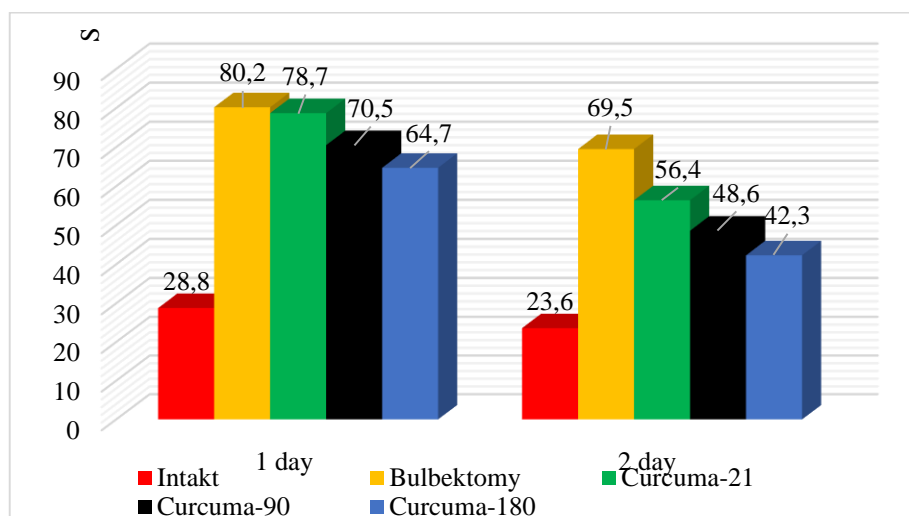


Figure 1. Time for rats to find a platform in the Morris water maze after 2 days of training

On microscopic examination, the capillary vessels of the retina and surrounding connective tissues have a thin structure, lined with a basal layer and endothelial cells. The cells that make up the cornea have an epithelial structure. The stroma is rich in fine connective tissue and the cells lining the inner surface of the cornea are endothelial cells (Figure 2a).

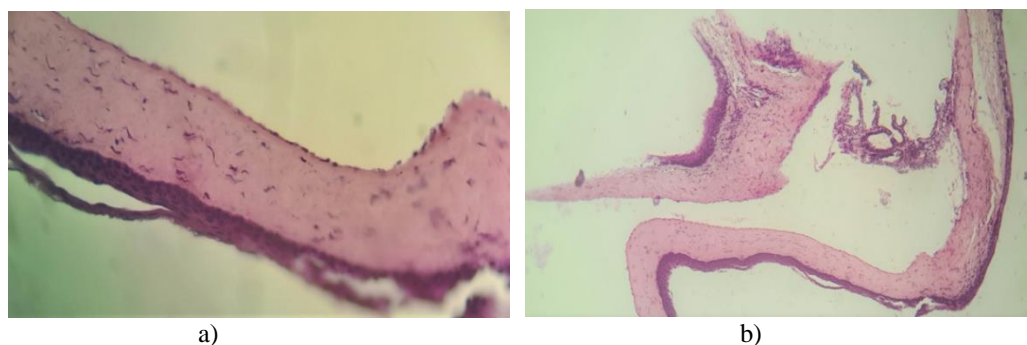


Figure 2. Histological structure of the cornea of the rat eye Control group. (a), rat eyes 7 days after bulbar brain lesion. Dye. hematoxylin-eosin: 40x increase (b).

Microscopic examination reveals edematous areas of hemorrhage and blood-filled capillaries in the retina and surrounding connective tissues. The basal layer was swollen and collagen fibers in focal areas were subject to mucous swelling. There are neutrophilic leukocytes associated with inflammation and endothelial cells with reactive enlarged nuclei associated with inflammation. The number of glycogen inclusions in the cytoplasm of cells is reduced and therefore the cytoplasm is weakly stained (Figure 2 b).

Microvascular fat droplets are noted in the epithelial cells that make up the cornea. The rich thin connective tissue elements that make up the stroma are edematous and swollen. The nuclei of the endothelial cells lining the posterior surface of the cornea are karyopyknotic.

Microscopic examination reveals blood-filled capillaries in the retina and surrounding connective tissues. Collagen fibers located in the basal layer form a somewhat fibrous structure. Endothelial cells with reactive enlarged nuclei lining the cornea are noted. Glycogen supplements were collected in the cytoplasm of the cells. Proliferation is noted in the epithelial cells that make up the cornea. The number of rich thin connective tissue elements that make up the stroma has increased (Figure 3 a).

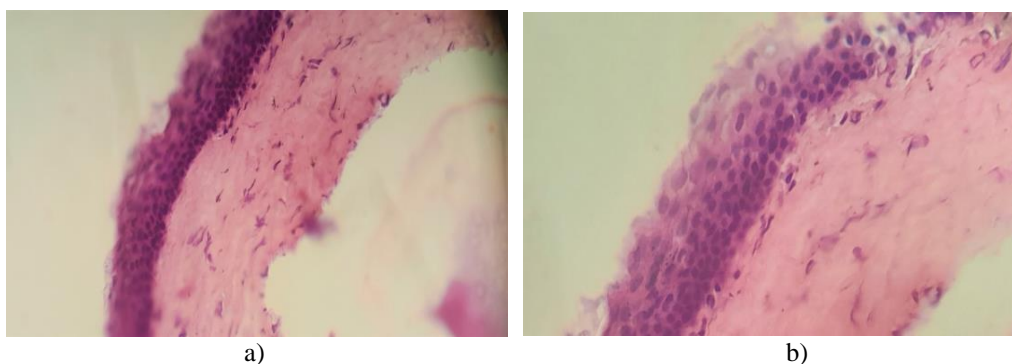


Figure 3. Retinas of rats treated with curcuma extract suspension for 21 days after bulbar traumatic brain injury (a). Retinas of rats treated with curcuma extract suspension on day 90 after bulbar traumatic brain injury (b). The dye is hematoxylin-eosin. Magnification X200

Microscopic examination shows that the thickening of the retinal epithelial layer has increased due to cell proliferation. In the epithelial layer of the retina, lymphocytic infiltration is observed in focal areas. Retinal epithelial cells have pinkish cytoplasm and a centrally located nucleus (Figure 3 b).

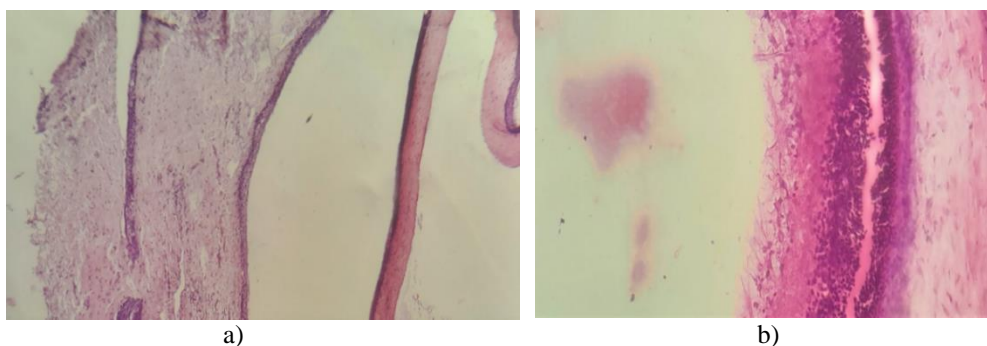


Figure 4. Retinas of rats treated with curcuma extract suspension from days 7 to 180 of bulbar traumatic brain injury. Hematoxylin-eosin dye. Magnification X 100 (a), X 200 (b)

On microscopic examination, the epithelial layer of the retina was clearly and evenly located and proliferated. In the stroma, collagen fibers are arranged in an orderly manner in the form of thin fibers. Proliferation of glial cells around the optic nerve is noted (Figure 4 a, b).

Bulbus olfactory, along with the hippocampus, contains multipotent stem cells in the adult brain. Bulbus olfactory gives numerous cholinergic projections to the hippocampus and neocortex. Removal of the bulbus olfactorius leads to cholinergic deficits, accumulation of beta-amyloid in the neocortex and hippocampus and cognitive deficits manifested in impaired spatial memory and orientation.

Olfactory bulbectomy results in changes in behavior and in the endocrine, immune and neurotransmitter systems that mimic many of those seen in depression. The olfactory system in the rat forms part of the limbic region, in which the amygdala and hippocampus contribute to emotional and behavioral memory components. The olfactory bulbectomy rat is not only a model for detecting antidepressant activity, but also a model for studying the relationships between these systems, which are also disrupted in major depression.

3. Conclusion

The results of the study indicate impairment of visuospatial memory and cognitive functions in bulbectomized animals. Compared to intact animals, these animals have difficulty finding the platform and their time is lengthened. Further research shows that taking curcuma restores memory in animals with bulbectomy. This effect was more pronounced in animals that took curcuma for a longer period of time. Histological analyzes also show that destructive changes in the retina of animals are restored after taking curcuma. From the literature it is known that curcumin inhibits the formation and promotes the disaggregation of β -amyloid plaques, attenuates tau hyperphosphorylation and enhances its clearance, binds copper, reduces cholesterol levels, modifies microglial activity, inhibits acetylcholinesterase, mediates the insulin signaling pathway and is an antioxidant (Tang *et al.*, 2017).

References

- Alber, J., Bouwman, F., den Haan, J., Rissman, R.A., De Groef, L., Koronyo-Hamaoui, M. & Thal, D.R. (2024). Retina pathology as a target for biomarkers for Alzheimer's disease: Current status, ophthalmopathological background, challenges and future directions. *Alzheimer's & Dementia*, 20(1), 728-740. <https://doi.org/10.1002/alz.13529>
- Asanad, S., Ross-Cisneros, F.N., Nassisi, M., Barron, E., Karanjia, R. & Sadun, A.A. (2019). The retina in Alzheimer's disease: Histomorphometric analysis of an ophthalmologic biomarker. *Investigative Ophthalmology & Visual Science*, 60(5), 1491-1500. <https://doi.org/10.1167/iovs.18-25966>
- Ashok, A., Singh, N., Chaudhary, S., Bellamkonda, V., Kritikos, A.E., Wise, A.S. & Ayyagari, R. (2020). Retinal degeneration and Alzheimer's disease: An evolving link. *International Journal of Molecular Sciences*, 21(19), 7290. <https://doi.org/10.3390/ijms21197290>
- Fernandes, F., Barroso, M.F., De Simone, A., Emriková, E., Dias-Teixeira, M., Pereira, J.P. & Grosso, C. (2022). Multi-target neuroprotective effects of herbal medicines for Alzheimer's disease. *Journal of Ethnopharmacology*, 290, 115107. <https://doi.org/10.1016/j.jep.2022.115107>
- Furlan, V., Konc, J. & Bren, U. (2018). Inverse molecular docking as a novel approach to study anticarcinogenic and anti-neuroinflammatory effects of curcumin. *Molecules*, 23(12), 3351. <https://doi.org/10.3390/molecules23123351>

- Long, Y., Li, D., Yu, S., Shi, A., Deng, J., Wen, J. & Han, L. (2022). Medicine–food herb: *Angelica sinensis*, a potential therapeutic hope for Alzheimer's disease and related complications. *Food & Function*, 13(17), 8783-8803. <https://doi.org/10.1039/d2fo01287a>
- Moons, L., De Groef, L. (2022). Multimodal retinal imaging to detect and understand Alzheimer's and Parkinson's disease. *Current Opinion in Neurobiology*, 72, 1-7. <https://doi.org/10.1016/j.conb.2021.07.007>
- Panahkova, E., Hashimova, U., Miryusivova, Kh., Allahverdiyeva, A., Huseynova, N. & K. Javadova. (2022). *Alzheimer Disease Vision, Amygdala, Epilepsy*, 214. Generis Publishing.
- Patton, N., Aslam, T., MacGillivray, T., Pattie, A., Deary, I.J. & Dhillon, B. (2005). Retinal vascular image analysis as a potential screening tool for cerebrovascular disease: A rationale based on homology between cerebral and retinal microvasculatures. *Journal of Anatomy*, 206(4), 319-348. <https://doi.org/10.1111/j.1469-7580.2005.00395.x>
- Pradeep, S., Prabhuswaminath, S.C., Reddy, P., Srinivasa, S.M., Shati, A.A., Alfaihi, M.Y. & Kollur, S.P. (2022). Anticholinesterase activity of *Areca Catechu*: In vitro and in silico green synthesis approach in search for therapeutic agents against Alzheimer's disease. *Frontiers in Pharmacology*, 13, 1044248. <https://doi.org/10.3389/fphar.2022.1044248>
- Suh, A., Ong, J., Kamran, S.A., Waisberg, E., Paladugu, P., Zaman, N. & Lee, A.G. (2023). Retina oculomics in neurodegenerative disease. *Annals of Biomedical Engineering*, 51(12), 2708-2721. <https://doi.org/10.1007/s10439-023-03365-0>
- Tang, M., Taghibiglou, C. (2017). The mechanisms of action of curcumin in Alzheimer's disease. *Journal of Alzheimer's Disease*, 58(4), 1003-1016.
- Tao, T.Z., Wang, L. & Liu, J. (2023). Role of corn silk for the treatment of Alzheimer's disease: A mechanism research based on network pharmacology combined with molecular docking and experimental validation. *Chemical Biology & Drug Design*, 102(5), 1231-1247. <https://doi.org/10.1111/cbdd.14315>
- Teter, B., Morihara, T., Lim, G.P., Chu, T., Jones, M.R., Zuo, X. & Cole, G.M. (2019). Curcumin restores innate immune Alzheimer's disease risk gene expression to ameliorate Alzheimer pathogenesis. *Neurobiology of Disease*, 127, 432-448.
- Van der Heide, F.C., Khawaja, A., Berendschot, T.T., Littlejohns, T.J., Kuźma, E., Luben, R. & Stehouwer, C.D. (2024). Associations of inner retinal layers with risk of incident dementia: An individual participant data analysis of four prospective cohort studies. *Alzheimer's & Dementia*, 20(1), 211-220. <https://doi.org/10.1002/alz.13167>
- Wang, X., Wu, J., Yu, C., Tang, Y., Liu, J., Chen, H. & Qin, D. (2017). Lychee seed saponins improve cognitive function and prevent neuronal injury via inhibiting neuronal apoptosis in a rat model of Alzheimer's disease. *Nutrients*, 9(2), 105.
- Wu, X., Zheng, X., Tang, H., Zhao, L., He, C., Zou, Y. & Ye, G. (2022). A network pharmacology approach to identify the mechanisms and molecular targets of curcumin against Alzheimer disease. *Medicine*, 101(34), e30194. <https://doi.org/10.1097/MD.00000000000030194>
- Yoon, S.P., Grewal, D.S., Thompson, A.C., Polascik, B.W., Dunn, C., Burke, J.R. & Fekrat, S. (2019). Retinal microvascular and neurodegenerative changes in Alzheimer's disease and mild cognitive impairment compared with control participants. *Ophthalmology Retina*, 3(6), 489-499. <https://doi.org/10.1016/j.oret.2019.02.002>
- Zhang, Y., Wang, Y., Shi, C., Shen, M. & Lu, F. (2021). Advances in retina imaging as potential biomarkers for early diagnosis of Alzheimer's disease. *Translational Neurodegeneration*, 10, 1-9. <https://doi.org/10.1186/s40035-021-00230-9>
- Zuhair, V., Rangwala, H.S., Mughal, Z.U.N., Fatima, H., Shaikh, A.T. & Mussarat, A. (2023). Viewing the brain through retina: A new avenue for early diagnosis of Alzheimer's disease. *Annals of Neurosciences*, 30(4), 219-221. <https://doi.org/10.1177/09727531231190992>